



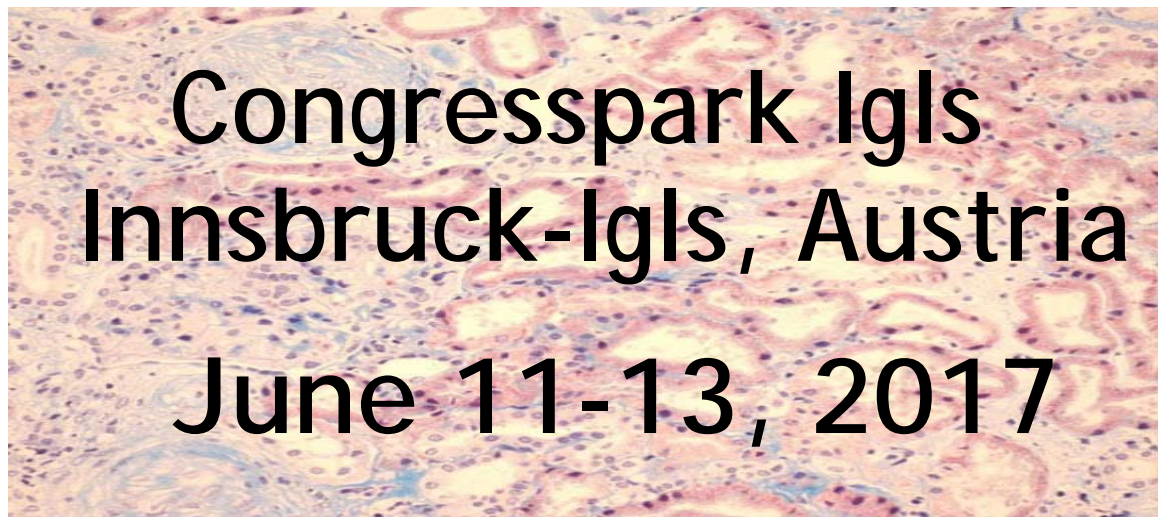
6th International Conference

HUS

& related disorders

Current diagnosis and therapy of
hemolytic uremic syndrome (HUS),
and related disorders

in cooperation with HOROS  doctoral programme



INTRODUCTION



Dear colleague,

Welcome to the 6th International HUS conference, again in Innsbruck-Igls where those who attended in 2015 could enjoy a relaxing atmosphere. I think it is probably completely dispensable to say that HUS stands for haemolytic uremic syndrome, but, of course, the correct way of introduction. As a lot of participants will attend for the second, third or even fourth time, it feels like meeting old friends. The conference in 2011 became quite famous as it took place just at the time of the EHEC O104:H4 outbreak in Northern Germany and for this reason gained world-wide attention. For the present 2017 meeting we will discuss *Escherichia coli*-induced HUS (eHUS), atypical HUS (aHUS) and other causes of HUS in detail, as before, particularly the increasing reports on treatment with the humanized anti-C5 inhibitor Eculizumab. Having characterised the first murine anti-human C5 monoclonal antibody, N19-8, in Göttingen myself, more than two decades ago, I find it extremely fascinating to see how the concept of complement inhibition made its successful way into the clinics.

This is the sixth time in eight years that we will host a meeting on HUS and related diseases in the Innsbruck area. This series was inaugurated by the unforgettable Lothar-Bernd Zimmerhackl, who was the main organiser of the first two meetings (and died already almost 7 years ago).

Innsbruck is the capital of the Alps, a twice Olympic city (1964, 1976) and medieval Habsburg dynasty town. This year we will have the Tyrolian gala dinner for the first time on the top of Innsbruck's local mountain, the Patscherkofel, providing a magnificent view. In any case we hope that you have some special relaxing time outside the programme.

Enjoy the scientific presentations, the exchange with specialists, the landscape and of course the Tyrolian gala night at the mountain top!

Wishing you all a great time in Innsbruck-Igls,



Reinhard Würzner
on behalf of

Thomas Giner, Johannes Hofer,
Therese Jungrathmayr, Dorothee Orth-Höller,
Magdalena Riedl & Alejandra Rosales

LOCAL ORGANIZING COMMITTEE

Thomas Giner, MD
Department of Pediatrics, Medical University of Innsbruck

Johannes Hofer, MD
Konventhospital, Barmherzige Brüder, Linz

Therese Jungraithmayr, MD, Priv.-Doz.
Department of Pediatrics, Pediatric Nephrology Centre, Memmingen

Dorothee Orth-Höller, MD, Priv.-Doz.
Division of Hygiene & Med. Microbiology, Medical University of Innsbruck

Magdalena Riedl, MD
Cell Biology Program, Research Inst., Hosp. for Sick Children, Toronto

Alejandra Rosales, MD, PhD
Department of Pediatrics, Medical University of Innsbruck

Reinhard Würzner, MD, PhD, Assoc. Prof.
Division of Hygiene & Med. Microbiology, Medical University of Innsbruck
Congress President

INFORMATION

Reinhard Würzner, MD, PhD
reinhard.wuerzner@i-med.ac.at
www.hus-online.at

PROGRAMME

Sunday, June 11

13:00 - 18:45 Lectures and Free Communications

19:00 - 21:00 *Welcome reception at the conference site*

Monday, June 12

08:30 - 17:30 Lectures and Free Communications

19.00 *Tyrolean Night at Patscherkofel*

Tuesday, June 13

08:30 - 12:30 Lectures and Free Communications

Sunday, June 11

10:00-18:30 Registration open

12:45 Welcome

I. Atypical hemolytic uremic syndrome (aHUS)

Chairs: B. Hetzer, G. Mayer

- 13:00 **L1** aHUS – Role of complement and surface recognition
S. Meri, FI
- 13:30 **L2** aHUS – Role of lectin pathway & coagulation, update
P. Garred, DK
- 14:00 **L3** aHUS – Role of endothelial cells
M. Riedl, CA
- 14:30 **FC1** A new mechanism of HUS: Blocking of factor H-mediated complement regulation by *Campylobacter jejuni*-induced anti-ganglioside antibodies
K. Hendrikson, FI

14:45-15:15 Coffee break

II. HUS & related disorders

Chairs: M. Rudnicki, S. Waldegger

- 15:15 **L4** aHUS – spectrum of involved molecules & mutations
M. Lemaire, CA
- 15:45 **L5** C3G: Pathology and characterization of the deposits
S. Sethi, US
- 16:15 **L6** Precision Medicine for DDD and C3G – new insights
R.J. Smith, US
- 16:45 **FC2** Morphological and immunohistochemical presentation of complement disorders in native and transplant renal biopsies
C. Aigner, AT

17:00-17:30 Coffee break

III. E. coli associated Hemolytic uremic syndrome (eHUS)

Chairs: C. Speth, G. Ariceta

- 17:30 **L7** Cytotoxic action of Shiga toxin on human erythrocyte progenitor cells
J. Müthing, DE
- 18:00 **FC3** Differential gene expression of human kidney cells in response to Shiga toxin 2a
I.U. Kouzel, DE
- 18:15 **L8** Shiga toxin effects in the blood
M. Brigotti, IT

19:00 Welcome reception at the Congresspark Igls

Monday, June 12

IV. **E. coli associated hemolytic uremic syndrome (eHUS) & complement**

Chairs: H. Stoiber, C. Lass-Flörl

- 08:30 **L9** Podocytes and anaphylatoxins
M. Morigi, IT
- 09:00 **FC4** The importance of podocytes complement factor H
A. Dettmar, DE
- 09:15 **L10** Interaction of EHEC and Shiga toxin with complement
D. Orth-Höller, AT

09:45-10:15 Coffee break

IV. **Prognostic markers and outcome of eHUS & eHUSc**

Chairs: T. Sawai, A. Waters

- 10:15 **FC5** A simple and prognostic index for STEC-HUS at presentation
F. Tel, IT
- 10:30 **FC6** Shorter duration of symptoms is associated with an increased severity of diarrhea associated HUS
W. Wong, NZ
- 10:45 **FC7** Long-term outcome of HUS: development of sequelae 10 years after acute disease
A. Rosales, AT
- 11:00 **L11** eHUSc – a new eHUS network
N. van de Kar, NL

11:30-12:30 Lunch break

12:30 **Poster session with dessert**

Chairs A: J. Martini, M. Riedl

Chairs B: T. Giner, D. Orth-Höller

Chairs C: A. Rosales, T. Jungraithmayr

VI. **Algorithms of investigations in HUS**

Chairs: T. Müller, A. Moschen

- 14:00 **L12** Algorithm of complement lab investigations, quality control
Z. Prohászka, HU
- 14:30 **L13** Indication & interpretation of genetic analysis for aHUS patients
S. Rodriguez de Cordoba, ES
- 15:00 **FC8** Algorithm of investigations in non-first world countries
H. Safouh, EG
- 15:30 **FC9** Illustrative case presentation for aHUS differential diagnosis
C. Bereczki, HU

15:30-16:00 Coffee break

VII. Animal models & Treatment with Eculizumab

Chairs: G. Weigel, J. Brunner

- 16:00 **L14** Novel C3 gain of function mouse model of aHUS
K. Marchbank, UK
- 16:30 **L15** Mode of action of eculizumab
G.R. Andersen, DK
- 17:00 **L16** Treatment of aHUS with eculizumab – update
C. Bedrosian, Alexion Pharmaceuticals, US

19:00 Tyrolean night at Patscherkofel

Tuesday, June 13

VIII. Eculizumab monitoring, Treatment without C inhibition

Chairs: J. Hofer, C. Mache

- 08:30 **L17** Monitoring eculizumab therapy & discontinuation
G. Ardissino, IT
- 09:00 FC10 Safety and effectiveness of restrictive Eculizumab treatment in aHUS
K.L. Wijnsma, NL
- 09:15 FC11 Eculizumab dosing regimen in aHUS: possibilities for individualized treatment
E. Volokhina, NL
- 09:30 FC12 Drug level monitoring in patients under Eculizumab
E. Trojnar, HU
- 09:45 **L18** Treatment of anti-factor H-associated HUS
A. Bagga, IN

10:15-10:45 Coffee break

IX. Treatment & monitoring using novel drugs

Chairs: K. Arbeiter, R. Würzner

- 10:45 **L19** Novel complement inhibitors, advantages & disadvantages
T.E. Mollnes, NO
- 11:15 **L20** Treatment using CR2-FH
M. Ruseva, UK
- 11:45 **L21** The therapeutic potential of LMW orally bioavailable AP inhibitors
R.A. Harrison, UK
- 12:15 Concluding remarks
R. Würzner, AT

12:30-14:00 Farewell and lunch

FACULTY

Adamczyk Piotr, Dept. of Pediatrics in Zabrze, Med. Univ. of Silesia, Katowice, Poland

Aigner Christoph, Dept. of Medicine III, Division of Nephrology and Dialysis, Medical University of Vienna, Vienna, Austria

Alzabli Saeed M, Pediatric Nephrology, Children Specialized Hospital, King Fahad Medical City, Riyadh, Saudi Arabia

Andersson Gregers Rom, Dept. of Mol. Biol. & Genet., Aarhus Univ., Denmark

Aradottir Sunna, Dept. of Pediatrics, Clinical Sciences Lund, Lund Univ., Lund, Sweden

Arbeiter Klaus, Dept. of Pediatrics, Medical University of Vienna, Vienna, Austria

Ardissino Gianluigi, Dept. of Pediatrics, Fondazione IRCCS Ca' Granda Osp. Maggiore Policlinico, Milano, Italy

Ariceta Gema, Pediatric Nephrology, Univ. Hosp. Vall d'Hebron, Barcelona, Spain

Bagga Arvind, Division of Nephrology, Dept. of Pediatrics, All India Institute of Med. Sciences, New Delhi, India

Bedrosian Camille, Alexion Pharmaceuticals Inc., New Haven, USA

Berezki Csaba, 3rd Dept. of Medicine, Semmelweis Univ. Budapest, Hungary

Brigotti Maurizio, Dept. of Experimental, Diagnostic and Specialty Medicine, Univ. of Bologna, Bologna, Italy

Brunner Jürgen, Dept. of Pediatrics, Med. Univ. of Innsbruck, Austria

Chatterjee Sneha, Division of Hygiene and Med. Microbiology, Med. Univ. of Innsbruck, Austria

Colucci V, Division of Nephrology, Univ. of Bari, Italy

Dettmar Anne, Dept. of Pediatric Nephrology, Univ. Med. Center Hamburg-Eppendorf, Germany

Di Leo Vincenzo, Division of Nephrology, Azienda Ospedaliero-Univ. Policlinico and Univ. of Bari, Italy

Gaggi Martina, Dept. of Medicine III, Div. of Nephrology and Dialysis, Med. Univ. Vienna, Austria

Garred Peter, Laboratory of Molecular Medicine, Dept. of Clinical Immunology, Rigshospitalet, Univ. Hosp. of Copenhagen, Denmark

Giner Thomas, Dept. of Pediatrics, Med. Univ. of Innsbruck, Austria

Hetzer Benjamin, Pediatrics Dept., Med. Univ. of Innsbruck, Austria

Hidaka Yoshihiko, Dept. of Pediatrics, Shinshu Univ. School of Medicine, Matsumoto, Nagano, Japan

Hendrikson K, Dept. of Bacteriology and Immunology, Univ. of Helsinki, Helsinki

Harrison Richard, Inst. of Infection & Immunity, Cardiff Univ., UK

Hofer Johannes, Konventhospital, Barmherzige Brüder, Linz, Austria

Hunley TE, Pediatric Nephrology, Monroe Carell Jr. Children's Hospital at Vanderbilt, Nashville, Tennessee, USA

Jarque A, Nephrology Services of HUNSC, Santa Cruz de Tenerife Spain

Johansson Karl, Dept. of Pediatrics, Clinical Sciences Lund, Lund, Sweden

Jungraithmayr Therese, Dept. of Pediatrics, Pediatric Nephrology Centre, Memmingen, Germany

Karnišová Lucia, 2nd Faculty of Medicine, Charles Univ. in Prague, Czech Republic

Kouzel Ivan, Institute for Hygiene, University of Münster, Germany

Lemaire Mathieu, Div. of Nephrology, Hosp. for Sick Children, Toronto, Canada

Lass-Flörl Cornelia, Division of Hygiene and Med. Microbiology, Med. Univ. of Innsbruck, Austria

Lungu Adrian Catalin, Fundeni Clinical Institute, Bucharest, Romania

Mache Christoph, Pediatrics Dept., Med. Univ. of Graz, Austria

Marchbank Kevin, Inst. of Cell. Med., Med. School, Newcastle Univ., UK

Martini Judith, Clinic of Anaesthesia & General Intensive Care Medicine, Med. Univ. of Innsbruck, Austria

Mayer Gert, Dept. of Nephrology, Med. Univ. of Innsbruck, Austria

Meri Seppo, Dept. of Bacteriology and Immunology, Haartman Institute, Univ. of Helsinki, Helsinki, Finland

Michels MA, Dept. of Pediatric Nephrology, Radboudumc, Nijmegen, the Netherlands

Mollnes Tom Eirik, Dept. of Immunology, Univ. of Oslo, Norway

Morigi Marina, Istituto di Ricerche Farmacologiche "Mario Negri", Bergamo, Italy

Moschen Alexander, Dept. of Internal Medicine, Med. Univ. of Innsbruck, Austria

Müller Thomas, Pediatrics Dept., Med. Univ. of Innsbruck, Austria

Müthing Johannes, Inst. for Hygiene, Univ. of Münster, Germany

Orth-Höller Dorothea, Division of Hygiene and Med. Microbiology, Med. Univ. of Innsbruck, Austria

Prohászka Zoltán, Illrd Dept. of Medicine, Semmelweis Univ. Budapest, Hungary

Riedl Magdalena, Cell Biology Program, Research Inst., Hosp. for Sick Children, Toronto

Rodriguez de Cordoba Santiago, Integrated Protein Science for Biomed. and Biotechnol. & CIB-CSIC, Madrid, Spain

Rosales Alejandra, Dept. of Pediatrics, Med. Univ. of Innsbruck, Austria

Rudnicki Michael, Dept. of Nephrology, Med. Univ. of Innsbruck, Austria

Ruseva Marieta, GSK, Brentford, UK

Safouh Hesham, Pediatric Nephrology Unit, Cairo Univ., Egypt

Sawai Toshihiro, TMA registry team, The Japanese Association for Complement Research, Osaka, Japan

Sethi Sanjeev, Lab. Med. & Pathology, Mayo Clinic, Rochester, MN, USA

Simankova Nadezda, Dept. of Paediatrics, 2nd Faculty of Medicine, Charles Univ. in Prague and University Hospital Motol

Smith Richard, Mol. Otolaryngology & Renal Research Lab., Carver College of Med., Univ. of Iowa, IA, USA

Speth Cornelia, Division of Hygiene and Med. Microbiology, Med. Univ. of Innsbruck, Austria

Stoiber Heribert, Division of Hygiene and Med. Microbiology, Med. Univ. of Innsbruck, Austria

Stolbova S, Department of Pediatrics, Second Faculty of Medicine, Charles Univ. in Prague and University Hospital Motol, Prague, Czech Republic

Tel Francesca, Center for HUS Prevention Control and Management at the Dept. of Pediatrics, Maggiore Policlinico, Milano, Italy

Trojnar Eszter, Füst György Research Laboratory, III. Department of Internal Medicine, Semmelweis University, Budapest

van de Kar Nicole, Med. Centre, Radboud Univ. Nijmegen, The Netherlands

Volokhina Elena B, Dept. of Pediatric Nephrology, Amalia Children's Hospital & Dept. of Laboratory Medicine, Radboud Univ. Med. Center, Nijmegen, The Netherlands

Waters Aiofe, Institute of Child Health, Great Ormond Street Hospital, London, UK

Waldegger Siegfried, Dept. of Pediatrics, Med. Univ. of Innsbruck, Austria

Weigel Günther, Central Institute for Med. and Chemical Laboratory Diagnostics, Med. Univ. of Innsbruck, Austria

Wijnsma Kioa, Dept. of Pediatric Nephrology, Radboud Univ. Med. Center, Nijmegen, The Netherlands

Wong William, Dept. of Pediatric Nephrology, Starship Children's Hospital, Auckland, New Zealand

Würzner Reinhard, Division of Hygiene and Med. Microbiology, Med. Univ. of Innsbruck, Austria

INVITED LECTURES (L6, L7)

L6

**PRECISION MEDICINE FOR DENSE DEPOSIT DISEASE AND C3 GLOMERULONEPHRITIS
- NEW INSIGHTS**

Smith RJ

Molecular Otolaryngology and Renal Research Laboratories, Carver College of Medicine, University of Iowa, Iowa City, IA, USA

C3 glomerulopathy (C3G) defines a group of ultra-rare complement-mediated renal diseases that share an underlying pathology - abnormal complement activation, deposition and regulation. Although significant knowledge gaps in the natural history of the two prototypical subtypes of C3G - Dense Deposit Disease (DDD) and C3 Glomerulonephritis (C3GN) - are lacking, a frequent outcome associated with either diagnosis is progression to end-stage renal disease. By completing a comprehensive examination of the complement system built on four pillars - genetic testing; functional assays of complement activity; measures of complement proteins and their cleavage products; and screens for autoantibodies - it is possible to generate a patient-specific assessment of on-going complement activity. These data can guide precision medicine for the individual patient. While a single disease-specific treatment is lacking, there are subsets of patients who may respond to eculizumab and/or mycophenolate mofetil. Furthermore, as clinical trials are initiated to test new anti-complement therapies in C3G patients, a thorough characterization of complement must be completed to ensure that observed clinical outcomes are appropriately interpreted.

L7

CYTOTOXIC ACTION OF SHIGA TOXIN ON HUMAN ERYTHROCYTE PROGENITOR CELLS

Müthing J, Karch H

Institute for Hygiene, University of Münster, Germany

Background: Hemolytic anemia is one of the characteristics of life-threatening extraintestinal complications in humans during infection with enterohemorrhagic *Escherichia coli* (EHEC). Shiga toxins (Stxs) of EHEC preferentially damage microvascular endothelial cells of the kidney and the brain, whereby occluded small blood vessels may elicit anemia through mechanical erythrocyte disruption.

Aim of the study: The aim of the study was to investigate whether Stx2a, the major virulence factor of EHEC, may cause direct cytotoxic effects on developing human erythrocytes.

Methods: We employed an *in vitro* erythropoiesis model using mobilized CD34⁺ hematopoietic progenitor cells from human blood and monitored expression of the Stx glycosphingolipid receptors globotriaosylceramide (Gb3Cer) and globotetraosylceramide (Gb4Cer) and Stx2a-mediated cellular injury of developing erythrocytes.

Results: CD34⁺ hematopoietic progenitor cells were negative for Stx2a receptors and resistant towards the toxin. Immediately after initiation of erythropoietic differentiation, expression of Stx2a-binding Gb3Cer and Gb4Cer and toxin sensitivity were apparent, peaked for basophilic and polychromatic erythroblast stages and declined during maturation into orthochromatic erythroblasts and reticulocytes, which became refractory to Stx2a.

Conclusions: Stx-mediated cytotoxic effects towards erythroblasts observed during the course of cell differentiation in our *in vitro* erythropoiesis model might contribute to the anemia caused by Stx-producing EHEC *in vivo*.

FREE COMMUNICATIONS (FC1 – FC12)

A NEW MECHANISM OF HUS: BLOCKING OF FACTOR H-MEDIATED COMPLEMENT REGULATION BY CAMPYLOBACTER JEJUNI-INDUCED ANTI-GANGLIOSIDE ANTIBODIES

Hendrikson K¹, Saariaho AH^{1,2}, Macdougall L³, Meri S^{1,2}

¹*Department of Bacteriology and Immunology, University of Helsinki, Helsinki;*
²*Research Programs Unit, Immunobiology, University of Helsinki, Helsinki;* ³*Renal Medicine, King's College Hospital, Denmark Hill, London, UK*

Background: Campylobacter infection is a rare but known antecedent of HUS. The complement regulator protein factor H (FH) inhibits complement by binding to the opsonin C3b and sialic acids on host cells. Sialic acids increase FH affinity for C3b. Campylobacter's cell-surface lipooligosaccharides molecularly mimic certain sialic acids of gangliosides and induce various neurological syndromes like Guillain-Barré-syndrome. In 2015 Bowen et al described a case of HUS after campylobacter gastroenteritis. We hypothesized that the patient could have developed antiganglioside antibodies.

Results: Serum samples were taken from the patient 3 and 18 months after the infection. At both time points IgG-type (but not IgM) antiganglioside GD3 antibodies were found (line blot assay, Generic Assays GmbH, Germany). Although anti-FH antibodies remained borderline by ELISA, reactivity against FH CCP19-20 was found. A homozygous deletion of FHR1-3 was confirmed by immunoblotting with polyclonal anti-FH antibodies. aHUS genetic screening for 13 genes (Secugen SP, Madrid, Spain and Blueprint Genetics, Helsinki, Finland) was negative. In exon 26 of the C3 gene a variant of unknown significance (c.3340C>T :p.Pro1114Ser) was observed. A nonsignificant heterozygous risk haplotype of the MCP gene (GCAC) was also found.

The results suggest that the patient's HUS episode was precipitated by a specific campylobacter infection, which led to formation of antiganglioside GD3 antibodies. By immunofluorescence microscopy with specific monoclonal antibody GD3 ganglioside was detected in the adult kidney glomeruli indicating that the target for the antiganglioside antibody is present in the kidney.

Conclusions: Based on the case we propose a novel mechanism of HUS due to formation of antiganglioside GD3 antibodies. The antibodies could impair FH-mediated complement regulation on endothelial and blood cells and trigger HUS. The model is in accordance with recent findings that impaired recognition of host cell sialic acids by FH triggers atypical HUS.

MORPHOLOGICAL AND IMMUNOHISTOCHEMICAL PRESENTATION OF COMPLEMENT DISORDERS IN NATIVE AND TRANSPLANT RENAL BIOPSIES

Aigner C¹, Gaggl M¹, Prohaszka Z², Altaleb A³, Sunder-Plassmann G¹, Schmidt A¹ and Kain R³

¹Department of Medicine III, Division of Nephrology and Dialysis, Medical University of Vienna, Vienna, Austria; ²IIIrd Department of Internal Medicine, Research Laboratory, Semmelweis University, Budapest, Hungary; ³Clinical Department of Pathology, Medical University of Vienna, Vienna, Austria

Background: Complement-mediated Thrombotic Microangiopathy (TMA), C3-glomerulonephritis (C3GN) and Dense Deposit Disease (DDD) are diseases of the alternative complement pathway and associated with the same genotypic background. However, the reasons for the different phenotypes remain unexplained.

Methods: We analysed 35 biopsies from 5 patients followed for an average of 14 years. All underwent renal transplantation (RTX) and analysis of morphologic and immunohistochemical parameters included light- and transmission electron-microscopy and immunohistochemical detection of immunoglobulins and proteins of the complement pathway (C1q, C3c, C3d, C4d, C5b-9).

Results: We identified 5 patients with complement associated disorders, all of which developed C3GN in the transplants (table 1). Treatment followed standard regimens in patients with biopsy proven rejection and 3 patients with persistent TMA received Eculizumab. All patients developed GN with a range of morphological presentation and variable C3d, C4d, no C5b-9, but prominent C3c deposits.

Conclusions: We here present 5 patients, all of which developed C3GN after RTX, which indicates a phenotype-switch between complement associated disorders. Neither mutations, nor deposition of complement products or the presence of rejection in renal biopsies allowed to predict presentation or outcome of disease. Our data indicate that a phenotype-switch may not be as rare as reported. However, morphological presentation may be influenced by therapies or graft rejection.

This work was supported by Alexion Pharma and by the National Research Fund of Hungary (OTKA K100687).

FC3

DIFFERENTIAL GENE EXPRESSION OF HUMAN KIDNEY EPITHELIAL CELLS IN RESPONSE TO SHIGA TOXIN 2a

Kouzel IU¹, Berger P¹, Steil D¹, Makatowski W², Suzuki Y³, Karch H¹, Müthing J¹

¹*Institute for Hygiene, University of Münster, Germany;* ²*Institute of Bioinformatics, University of Münster, Germany;* ³*Department of Computational Biology and Medical Sciences, University of Tokyo, Japan*

Background: Recent studies indicate that human kidney epithelial cells are highly susceptible to the cytotoxic action of Stxs and thus may contribute to the development of the hemolytic uremic syndrome (HUS) caused by EHEC. The human kidney epithelial cell lines ACHN and Caki-2 were found to harbor very similar amounts of the Stx receptor glycosphingolipids (GSLs) globotriaosylceramide (Gb3Cer) and globotetraosylceramide (Gb4Cer). Interestingly, ACHN cells were highly sensitive towards Stx2a, whereas Caki-2 cells were almost resistant, indicating that Stx receptor content alone does not determine Stx susceptibility.

Aim of the study: The aim of the study was to perform differential gene expression analysis of Stx-sensitive ACHN and Stx-resistant Caki-2 cells at different time points of Stx exposure to identify cell-specific differences in the expression of genes with emphasis on those involved with GSL receptor-related glycosyltransferases and the subcellular retrograde transport of endocytosed toxin.

Methods: We performed whole transcriptome profiling of ACHN and Caki-2 cells under exposure to Stx2a. The DESeq2 R/Bioconductor package was used for gene expression analysis.

Results: Stx-sensitive ACHN and Stx-resistant Caki-2 cells were found to respond markedly distinct upon exposure of the cells to Stx2a as detected by differential gene expression analysis. The higher sensitivity of ACHN cells towards Stx2a, when compared to Caki-2 cells, was found to relate to changed expression of numerous genes, particularly of those genes coding for proteins being involved in endosomal protein sorting, retrograde transport of Stx through the *trans* Golgi network and the Endoplasmic Reticulum as well as for pro-inflammatory cytokines.

Conclusions: Our results indicate that resistance of a certain cell type towards Stx, despite presence of Stx receptor GSLs, may be due to an altered expression of genes being involved in subcellular routing of the toxin leading to failure of Stx in reaching its intracellular targets. Such genes may represent potential targets for novel therapeutic strategies in the treatment of HUS.

THE IMPORTANCE OF PODOCYTES' COMPLEMENT FACTOR H

Dettmar A¹, Abt J¹, Steingröver J¹, Schwesinger CM², Licht C³, Saleem M⁴, Oh J¹

¹*Pediatric Nephrology, University Medical Center Hamburg-Eppendorf, Germany;*
²*III. Medical Clinic and Polyclinic, University Medical Center Hamburg-Eppendorf, Germany;*
³*The Hospital for Sick Children, Toronto, Canada,*
⁴*Bristol Renal and Children's Renal Unit, University of Bristol, Bristol, United Kingdom*

Background: Renal diseases with complement activation are often associated with proteinuria. Complement mediated damage to podocytes in membranous nephropathy leads to severe proteinuria. Little is known about the complement mediated damage and the protection of glomerular cells against systemic and local glomerular complement activation. Complement factor H (CFH) is known to regulate complement activation in serum and local cells and it was already shown that podocytes *in vivo* and *in vitro* express CFH.

Aim of the study: To evaluate the role of podocyte secreted factor H in glomerular complement activation.

Methods: Glomerular expression of CFH was tested in a murine model of immunologic induced (anti-podocyte nephritis = APN) and podocyte toxic induced (adriamycin=ADR) proteinuria. Human podocytes and endothelial cells were analyzed for their expression and secretion of CFH. Functionality of CFH was tested in a cofactor-assay.

Results: Immunologic induced proteinuria (APN) as well as podocyte toxic proteinuria (ADR) showed glomerular activation of complement. Isolated glomeruli of both animal models showed a significant enhanced production of CFH (relative CFH-mRNA expression: APN vs. control: 1.82±0.6 vs. 1.00±0.07, p=0.057, ADR vs. control: 1.55±0.29 vs. 1.01±0.16, p=0.036). As podocytes and glomerular endothelial cells could contribute to glomerular CFH expression, podocytes and endothelial cell lines (e.g. BOECs, glomerular endothelial cells) were compared. Podocytes showed a significant higher expression (2.6-fold, p<0.05) of CFH on mRNA and protein (2-fold, p<0.05) level. Podocyte secreted and membrane bound CFH showed its ability to split complement component C3b in a cofactor assay.

Conclusion: We could show an enhanced glomerular production of CFH in podocyte-damaging murine models. The source of this production seems to be the podocyte, as the production *in vitro* in podocytes is higher compared to endothelial cells. The secreted CFH might be able to protect glomerular cells from damage in complement mediated glomerular diseases.

A SIMPLE AND EARLY PRGNOSTIC INDEX FOR STEC-HUS AT PRESENTATION

Tel F¹, Testa S¹, Paglialonga F¹, Perrone M¹, Picicco D², Dodaro A², Daprai L², Colombo R², Arghittu M², Consonni D³, Ardissino G¹

Center for HUS Prevention Control and Management at the: ¹Dept. of Pediatrics; ²Laboratory of Microbiology; ³Epidemiology Unit, Fondazione IRCCS Ca Granda Osp. Maggiore Policlinico, Milano, Italy

Background: STEC-HUS is an unrare, severe acute thrombotic microangiopathy (TMA) burdened with life-threatening complications (Cs), high case-fatality rate and significant long term sequels. It is important, both for patient's (Pts) management and prognosis communication, to identify Pts at high risk for severe long-term Cs, as early as possible in the course of the disease possibly through a simple and straightforward approach. It has been demonstrated that hemoconcentration at presentation of STEC-HUS is associated with worse short- and long-term outcome.

Aim of the study: to identify and develop a reliable, as well as easy to calculate (at bedside), index to predict Cs.

Methods: the very first laboratoy examination with signs of TMA of Pts with STECHUS referred to our Center during recent years, were analyzed. The following outcomes were considered: 1. full recovery; 2. minor long-term renal sequels (CKD 1); 3. severe renal (CKD 2-5) and/or systemic sequels; 4. death. Receiver Opereiting Characteristic (ROC) and their area under the curve (AUC) for relevant continuous laboratory parameters at presentation, were calculated, after univariate and multiple logistic regression models.

Population: the data set of 180 patients (100 females) with documented STEC-HUS and with a mean age of 4.2 years (IR 1.6-6.0) were analyzed.

Results: Hb level at presentation alone proved to be the best predictor of poor outcome (AUC: 0.730). sCr at presentation showed an AUC of 0.662. However, the best prediction of long-term outcome was obtained with Hb combined with sCr (according to the following formula [(Hb in g/dL + (sCr in mg/dL x 2)] at presentation (eHUS Severity Score) with an AUC of 0.786 (CI 0.714-0.840).

Conclusions: We conclude that in STEC-HUS, Pts with high Hb level (>10 gr/dL) and those with lower Hb but already high sCr, at presentation should be carefully evaluated, monitored and managed accordingly for the very high risk of Cs (casefatality rate of 10% for eHUS Severity Score >15) most likely related to hidden hemoconcentration in ongoing TMA.

FC6

SHORTER DURATION OF SYMPTOMS IS ASSOCIATED WITH AN INCREASED SEVERITY OF DIARRHOEA ASSOCIATED HUS

Wong W¹, Kara T¹, Prestidge, CP¹, Morris MC¹, Ronaldson JE¹

¹Department of Nephrology, Starship Children's Hospital, Auckland, New Zealand

Background: Risk factors which may assist in predicting the clinical course are important in the care of children with D+HUS. The presence of severe extra-renal symptoms such as recurrent seizures, severe haemorrhagic colitis are associated with greater severity of acute kidney injury and risk of chronic kidney disease. A shorter duration symptoms may be associated with more severe disease as the development of significant anaemia and acute kidney injury may occur at an earlier stage and therefore be diagnosed earlier

Aim of the study: To show that patients with a short duration of symptoms have more severe disease

Patients and Methods: Between January 1, 1998 and December 31 2016, 206 children under age 15 were diagnosed with HUS were reported to the principal investigator through the New Zealand Paediatric Surveillance Unit. 174 had a diarrheal prodrome and this cohort was arbitrarily divided into group 1, n=69 (diarrhoea \leq 5 days) and group 2, n=105 (diarrhoea \geq 6 days).

Results: Group 1 children had more severe clinical course with higher likelihood of anuria, longer duration of anuria and consequently a longer period of dialysis. Group 1 children also had significantly higher neutrophil counts than group 2 patients.

Conclusions: Children with short duration of symptoms before the diagnosis of HUS are at higher risk of more severe disease and therefore anticipatory measures may be instituted earlier to mitigate complications of HUS.

FC7

LONG-TERM OUTCOME OF E. COLI INDUCED HEMOLYTIC UREMIC SYNDROME (EHUS): DEVELOPMENT OF SEQUELAE 10-YEARS AFTER ACUTE DISEASE

Rosales A, Kuppelwieser S, Giner T, Hofer J, Riedl M, Orth-Höller D, Würzner R, Jungraithmayr T

Medical University of Innsbruck, Austria

Objectives: HUS is one of the main causes of acute renal failure in children. The typical form of HUS is caused by EHEC-bacteria (eHUS). The aim of this study was to evaluate the long-term prognosis of children with eHUS 10 years after the acute phase of disease and identify risk factors for poor long term outcome.

Methods: Over a 6-year period 619 pediatric patients with the clinical diagnosis of eHUS (490 EHEC-positive, 79%) were registered in Austria and Germany. The patients were examined 1, 2, 3, 5 and 10 years after the acute phase in relation to long-term sequelae. The data of 139 eHUS-patients were evaluable after 10 years.

Results: 65% of EHEC infected patients were fully recovered and showed no abnormalities. The remaining 35% (n=47) had persistent hypertension (17%), neurological symptoms (3%), decreased glomerular filtration rate (3%) and/or proteinuria (23%). 30 of this 47 patients had symptoms already 1 year after eHUS, the rest presented sequelae for the first time at the 2-year (n=3), 3-year (n=3), 5-year (n=2) or 10-year (n=9) follow-up. 2% (n=10) of the initially 490 registered eHUS-patients received a kidney transplant. This study identified, among other factors, like the detection of Shiga toxin 2 in the stool ($p=0,04$) and use of erythrocyte concentrates ($p=0,041$), an association between the need of dialysis or plasmapheresis and the presence of symptoms after 10 years ($p<0.05$), but these treatments were also used in more severe cases. Since the 10-year-follow-up data were only available from 28% of the patients and the remaining 72% are probably recovered patients, the prevalence of the frequencies calculated here could be significantly lower in the total population.

Conclusion: Patients with eHUS should be examined regularly 10 years after the acute phase of eHUS, because long-term sequelae can still occur even many years after the acute phase. Risk factors that may point to the development of poor long-term outcome, are an initial serious illness marked by plasma treatment and dialysis as well as the use of erythrocyte concentrates and the detection of Shiga toxin 2 in the acute phase.

FC8

ALGORITHM OF HUS INVESTIGATIONS IN NON-FIRST WORLD COUNTRIES

H. Safouh

Pediatric Nephrology Unit, Cairo Univ., Egypt

HUS is considered a rare disease. The laboratories and facilities required for an accurate and definitive diagnosis of many rare diseases, including HUS, may be lacking in many centers resulting in misdiagnosis, and/or a delay in correct diagnosis and therapy. This is particularly true in non-first world countries.

The initial diagnosis of HUS is based on the golden triad of a skilled history taking, the clinical status and a systematic diagnostic work-up. aHUS has to be differentiated from other forms of HUS and from thrombotic thrombocytopenic purpura (TTP). Although several guidelines and articles have been published recently from different HUS expert groups describing algorithms for HUS investigations, and since the diagnostic and opportunities in the developing world differ substantially from those evidence-based and expert-based recommendations, establishing a cost effective and fast, stepwise approach for the work-up of HUS patients adapted to the diagnostic and financial possibilities in developing regions is a primary goal. The most important diagnostic tools include Stx detection by ELISA, ADAMTS13 activity measurement, and CFH-Ab testing together with a basic laboratory work-up. Establishing cooperations with international centers of competence for further steps of diagnostic work-up and for the discussion of results is also required. However, sending the necessary samples from developing countries to such international centers is frequently time and cost consuming and may delay management decisions.

Some non-first world countries have recently made great strides in the introduction of advanced HUS investigations including genetic tests in their own research labs. The private sector (commercial labs) in such regions is also able to provide rapid and efficient, though quite expensive, diagnostic services.

This presentation attempts at describing the current status of HUS diagnostic testing in non-first world countries compared to the state of the art recommendations, and to suggest different approaches to overcoming such diagnostic difficulties.

ILLUSTRATIVE CASE PRESENTATION FOR AHUS DIFFERENTIAL DIAGNOSIS: AN EXCEPTION FROM THE AHUS THERAPEUTIC GUIDELINES

Bereczki C¹, Jakab D¹, Szigeti E¹, Csuka D², Prohászka Z^{2,3}

¹Department of Pediatrics, University of Szeged, Szeged, Hungary; ²³rd Department of Internal Medicine, Research Laboratory and George Füst Complement Diagnostic Laboratory, Semmelweis University, Budapest, Hungary; ³Research Group of Immunology and Hematology, Hungarian Academy of Sciences and Semmelweis University

Background: Atypical hemolytic uremic syndrome (aHUS) is a complex disorder with multiple potential triggering and etiological factors leading to the development of thrombotic microangiopathy. Diacylglycerol kinase epsilon (DGKE) plays an important regulating role in the arachidonic acid signaling pathway, by phosphorylating arachidonic acid and inhibiting the activation of protein kinase C.

Objectives: With the presentation of this exceptional case history the aim of our work is to illustrate how rapid clinical, complement diagnostic and genetic analysis may support clinical decision making and management.

Case history: We report the rare case of a 2 years old Caucasian, non-consanguineous girl who developed aHUS based on combined predisposing factors in *DGKE* (diacylglycerol kinase epsilon). At the time of admission, she showed nephroso-nephritic symptoms, paleness with mild jaundice. Laboratory results showed anemia, thrombocytopenia, increased LDH, Coombs negative hemolysis, and maintained kidney function. Urine analysis showed nephrotic range proteinuria and mild haematuria. Because of the nephroso-nephritic symptoms kidney biopsy was done, the result was indicative for thrombotic microangiopathy. Complement diagnostic analysis proved no signs of hypocomplementemia or alternative pathway dysregulation, complement C3 was in normal range, ADAMTS 13 activity was moderately decreased.

After no improvement to parenteral high dose pulse steroid treatment and plasmapheresis, we started eculizumab treatment without further improvement in the patient condition or the laboratory result.

After we ruled out all the other potential causes of aHUS rapid genetic testing was initiated, and the result revealed compound heterozygote mutation with function loss of the *DGKE* gene. Eculizumab and plasma treatment was suspended since there were no relevant variations present in the complement regulators. Dialysis treatment was necessary for 1 month and after an additional month the TMA process turned into remission without severe sequel.

Conclusions: Rapid and detailed diagnostic workup, including complement profile and genetic analysis is necessary if aHUS is suspected, since results may influence clinical decision making and selection of appropriate therapy.

FC10

SAFETY AND EFFECTIVENESS OF RESTRICTIVE ECULIZUMAB TREATMENT IN ATYPICAL HEMOLYTIC UREMIC SYNDROME

Wijnsma KL¹, Duineveld C², Volokhina EB^{1,3}, van den Heuvel LP^{1,3,4}, van de Kar NCAJ¹, Wetzels JFM²

¹Dept. of Pediatric Nephrology, Radboudumc, Nijmegen, The Netherlands; ²Dept. of Nephrology, Radboudumc, Nijmegen, The Netherlands; ³Dept. of Laboratory Medicine, Radboudumc, Nijmegen, The Netherlands; ⁴Dept. of Pediatrics, University Hospital Leuven, Leuven, Belgium

Background: Atypical hemolytic uremic syndrome (aHUS), as a consequence of complement dysregulation, is associated with poor outcome. However, with the introduction of eculizumab in 2012, outcome has greatly improved. Currently, the duration of this treatment is debated. Most guidelines advise lifelong treatment. Even though, there is no hard evidence to support this advice. Historically, a substantial number of aHUS patients were weaned of plasma therapy, often without disease recurrence. Moreover, the long-term consequences of eculizumab treatment are unknown.

Aim of the study: In this retrospective study we describe 20 patients who received a restrictive treatment regimen.

Methods/Patients: All aHUS patients who presented in the Radboudumc, Nijmegen, the Netherlands, between 2012-2016, and who received eculizumab are described. Clinical, diagnostic and follow up data were gathered and reviewed.

Results: Twenty patients (14 adults, 6 children) with aHUS have received eculizumab. Eculizumab was tapered in all and stopped in 17 patients. Atypical HUS recurrence occurred in five patients. Due to close monitoring, recurrence was detected early and eculizumab was restarted. No clinical sequela such as proteinuria or progressive kidney dysfunction were detected subsequently. In total, eculizumab has been discontinued in 13 patients without aHUS recurrence, of which 5 are event free for over a year now. With this strategy approximately €11.5 million has been saved.

Conclusions: A restrictive eculizumab regimen in aHUS appears safe and effective, with close monitoring for signs of disease recurrence. Prospective studies are needed to determine optimal duration of treatment with eculizumab and evaluate prediction markers. Recently, a national, prospective study called CUREiHUS has started in the Netherlands.

FC11

ECULIZUMAB DOSING REGIMEN IN ATYPICAL HUS: POSSIBILITIES FOR INDIVIDUALIZED TREATMENT

Volokhina E^{1,2}, Wijnsma K¹, van der Molen R², Roeleveld N^{1,3}, van der Velden T¹, Goertz J², Sweep F², Brüggemann R⁴, Wetzels J⁵, van de Kar N¹, van den Heuvel L^{1,2,6}

Departments of ¹Pediatric Nephrology, Amalia Children's Hospital; ²Laboratory Medicine; ³Health Evidence; ⁴Pharmacy and ⁵Nephrology, Radboud university medical center, Nijmegen, The Netherlands; ⁶Department of Pediatrics, University Hospitals Leuven, Belgium

Background: Recent studies indicate that eculizumab is often given in excess to aHUS patients. Individualization of treatment is thus highly requested, however, data on pharmacokinetics and pharmacodynamics of eculizumab remain limited.

Aim of the study: In this study we analyzed eculizumab levels and complement activity in patients that received the drug according to standard and individualized treatment schemes.

Methods/Patients: Serum eculizumab and complement activity (CH50) were measured by in-house ELISA-based methods. In total, 209 samples were taken from 11 patients before the eculizumab infusion in the induction (weekly), maintenance (2-weekly) and tapering (every 3, 4 and 5 weeks) phases of therapy. Statistical analysis was performed using linear mixed models.

Results: The trough eculizumab levels increased with each additional dose during the induction phase (depending on body weight). During maintenance, high eculizumab concentrations of up to 772 µg/mL were observed. The levels decreased with each following dose during tapering (3- and 4-week intervals), however three patients maintained target eculizumab levels over long time periods (30-48 weeks). At intervals of 6-8 weeks target eculizumab levels were no longer attained. Serum samples with eculizumab concentrations ≥ 50 µg/mL showed adequate complement blockade.

Conclusions: Our data provide essential insight for optimization of eculizumab dosing schemes and lessening of therapy burden for the patients and cost of the treatment.

DRUG LEVEL MONITORING IN PATIENTS UNDER ECULIZUMAB TREATMENT

Trojnar E¹, Prohaszka Z¹

¹Füst György Research Laboratory, III. Department of Internal Medicine, Semmelweis University, Budapest

Background: Due to its inhibitory effect on terminal complement activation eculizumab (trade name: Soliris[®]) is used in a growing number of complement mediated diseases. Beside satisfactory clinical response upon admission, the efficacy of the drug can be monitored in patients through the blockade of the complement alternative (activity below 10%) and classical (less than 20 CH50/ml) pathway activation. However, conditions with controversial laboratory data require direct monitoring of serum free eculizumab level to reveal the background of the ongoing complement activation and help dose adjustment. Therefore our aim was to determine the exact serum level and the characteristics of excretion after drug administration in eculizumab-treated patients.

Methods: We received 230 sera and/or urine samples from patients who received eculizumab due to various indications (atypical haemolytic uremic syndrome, C3 glomerulopathy, myasthenia gravis, systemic lupus erythematosus and post bone-marrow transplantation thrombotic microangiopathy). Eculizumab levels in the samples were determined by an in-house ELISA method, serum free drug levels were calculated by non-linear regression from a standard of the drug. These results were correlated with the complement activation parameters of each patient for further evaluation.

Results: Regardless of the underlying disease, we had no detectable classical or alternative pathway activation with serum free eculizumab levels above 100 µg/ml, whereas patients with drug levels below 50µg/ml had detectable activity to a various extent. Nevertheless, the level of the terminal complement complex (sC5b-9) showed no correlation to the serum free drug level, raising the question, whether the prolonged complement activation is due to an augmented excretion of the drug or due to local complement activation at sites inaccessible for eculizumab.

Conclusion: The application of eculizumab in recommended doses provides an effective blockade of the complement system. However, conditions with increased risk of bleeding, hematuria or proteinuria require close monitoring of the serum free drug level, which contributes to the exploration of the background of improper clinical response. The key to rapid dose adjustment is the determination of the serum free drug level during the follow-up of patients. Our diagnostic method provides a practical option for routine determination of serum free eculizumab levels, and may help to improve management of patients under treatment.

POSTERS

Session A – eHUS, pHUS

Session B – aHUS

Session C – aHUS cases, Eculizumab

A1

P2X1 PURINERGIC BLOCKADE PROTECTS CELLS FROM SHIGA TOXIN-MEDIATED TOXICITY

Johansson K, Ståhl A, Karpman D

Department of Pediatrics, Clinical Sciences Lund, Lund, Sweden

Shiga toxin (Stx) may circulate within blood cell-derived microvesicles thus reaching its target organ, the kidney. Our group has previously shown that a non-specific purinergic receptor inhibitor, suramin, decreased microvesicle release from red blood cells. The aim of this study was to investigate if specific P2X1 blockade could protect cells from the effects of Stx. A specific P2X1 receptor antagonist, NF449, was used in *in vitro* studies to investigate its effects on Stx-mediated calcium influx, retrograde transport, toxicity and microvesicle release from HeLa cells. Stx 1 caused rapid calcium influx in HeLa cells loaded with fluo-4 calcium indicator as detected by fluorescence microscopy. NF449 pre-treatment abolished Stx-induced calcium influx completely. Once internalized Stx 1B-subunit:Alexa488 predominantly localized with golgin97 golgi marker. Pre-treatment with NF449 led to a more dispersed pattern of the toxin within the cytosol. Cells pre-treated with NF449 exhibited 13.5 % increased viability after exposure to Stx 2 for 24 hours, in comparison to untreated cells. Furthermore, Stx-2 induced microvesicle release from HeLa cells as measured by flow cytometry, an effect abolished by preincubation with NF449. P2X1 receptor blockade inhibited Stx-mediated calcium influx, the toxin's retrograde transport, cytotoxicity and microvesicle release and thus protected HeLa cells. These data imply that P2X1 blockade should be explored as a treatment for Stx-mediated disease as well as microvesicle-associated diseases in general.

A2

SHIGA TOXIN 2 BINDS TO MASP-3 - INVOLVEMENT OF LECTIN PATHWAY IN eHUS PATHOGENESIS?

Chatterjee S¹, Rosbjerg A², Striegel I¹, Huber S¹, Garred P², Orth-Höller D¹, Würzner R¹

¹*Div. of Hygiene and Med. Microbiology, Med. Univ. of Innsbruck, Austria;* ²*Lab. of Mol. Med., Dept. of Clin. Immunol., Rigshospitalet, Univ. of Copenhagen, Denmark*

Background: The role of complement in atypical Hemolytic Uremic Syndrome (aHUS) has been known to be caused by uncontrolled activation of the alternative pathway. Our group has previously shown that Shiga toxin 2 (Stx2), produced by Enterohemorrhagic *Escherichia coli* (EHEC), activates complement via the alternative pathway (AP) and also binds to factor H (FH) (Orth *et al.*, 2009), establishing the involvement of complement in the pathogenesis of EHEC associated HUS (eHUS). However, the association of Stx2 with the lectin pathway (LP) is poorly investigated and perhaps can provide further insights into eHUS pathogenesis. The lectin pathway proceeds with pattern recognition molecules (PRMs) binding to pathogenic surfaces leading to successive cleavage of LP proteins with the help of PRM-associated serine proteases (MASPs) which cleave C4 and C2, leading to C3 convertase and finally the potentially lytic terminal complement complex (TCC). Mannose-binding lectin (MBL)/ficolin/collectin-11-associated protein-1 (MAP-1), a transcriptional variant of *MASP1* gene, has shown to be an inhibitor of the LP (Skjoedt MO *et al.*, 2010).

Aim of the study: MASP-1 and MASP-3, both encoded by *MASP1* gene, consisting of a common heavy chain but distinct catalytic serine protease (SP) domains, are activators of the LP. MAP-1, resulting from a different *MASP1* gene splicing, consists of the majority of the heavy chain but no SP domain and act as an inhibitor of the LP. The present study was thus aimed to investigate whether Stx2 binds to rMASP-1 or rMASP-3, thus interfering with the advancement of complement attack.

Methods: Binding of Stx2 to rMASP-1, rMASP-3, rMAP-1 and rMASP heavy chain (rMASP-HC) was investigated by ELISA. Bovine serum albumin (BSA) in place of Stx2 or TBST-calcium buffer in place of rMASP-1, rMASP-3, rMAP-1 and rMASP-HC were taken into consideration as negative controls.

Results: The binding studies revealed that Stx2 binds to rMASP-3 and possibly, but to a lesser extent to rMASP-1. Stx2 does not bind to rMAP-1 or rMASP-HC.

Conclusions: With Stx2 binding to MASP-3 and possibly to MASP-1, which also activates MASP-3, our findings suggest the involvement of LP in eHUS pathogenesis.

A3

THE ROLE OF COMPLEMENT ACTIVATION IN PATIENTS WITH TYPICAL HUS IN CZECH REPUBLIC, THE RETROSPECTIVE STUDY

Karnišová L, Fencí F, Zieg J, Bláhová K

2nd Faculty of Medicine, Charles University, Prague, Czech Republic

Background: The main reason of development of typical HUS in patients with STEC infection is still unknown. The role of complement and the efficacy of treatment with C5-monoclonal antibody Eculizumab has been discussed recently.

Aim of the study: The aim of our study was to compare the clinical courses of patients with and without the activation of complement at the time of admission.

Patients and Methods: We performed a retrospective chart review of patients with typical HUS admitted to 3 pediatric dialysis centres in Czech Republic between 1999 and 2015. Patients were divided into two groups- Group 1 with C3 < 0,8 g/l as a sign of complement activation vs. Group 2 without complement activation with C3 > 0,8 g/l. Their clinical courses and laboratory values were statistically compared.

Results: During the 16-year period, 55 patients were identified. 36/55 (65,4%) patients underwent dialysis, 14/55 (25,45%) had neurologic complication, 4 patients died. C3 level was performed in 33/55 cases at admission (Group 1 N= 17, Group 2= 16 patients). Patients with decreased level of C3 showed significantly higher levels of creatinine (median 358 $\mu\text{mol/l}$ vs. 222 $\mu\text{mol/l}$, $p=0,03$), had significantly more extrarenal complications (11/17 vs. 4/16, $p=0,0216$) and stayed in hospital significantly longer (median time of 30, range 3-55 days vs. 17, range 9-37 days, $p=0,0428$). The need of RRT was significantly higher and the median duration of RRT was significantly longer in patient with complement activation (17/17 vs. 7/16, $P<0,0001$ and 15, ranges 3-27 days vs. 7, range 11-12 days, respectively). Both groups revealed no significant differences in laboratory markers as haemoglobin, platelets, lactate-dehydrogenase level and in the age of patients.

Conclusions: According to our results, the activation of complement in typical HUS could be the cause of severe course of this life threatening disease. Treatment of typical HUS is still mainly symptomatic and blockade of complement activation should be considered in patients with signs of its activation at admission.

Diarrhea Associated Hemolytic Uremic Syndrome (D+ HUS): A Single Center Experience from a High Incidence Area

Hunley TE¹, Yackley J², Guelich SF³, Garman K², Vandevoorde RGIII¹, Jones DP¹, Dunn JR², Jabs K¹

¹*Pediatric Nephrology, Monroe Carell Jr. Children's Hospital at Vanderbilt, Nashville, Tennessee (TN);* ²*Tennessee Department of Health, Nashville, Tennessee;* ³*Virginia Tech Carilion School of Medicine, Roanoke, Virginia*

Background: D+HUS remains a clinical challenge, lacking specific therapy. Recent data from the U.S. Centers for Disease Control suggest a high incidence of D+ HUS in TN.

Aim of the study: To describe a contemporary cohort of D+ HUS patients and ascertain incidence rates for STEC and D+ HUS in TN.

Patients / Methods: This is a retrospective cohort study of all pediatric patients with D+ HUS 1999 - 2016 analyzing presentation, course, and outcome. Participation of the TN Dept of Health in the Foodborne Diseases Active Surveillance Network (FoodNet) allowed enhanced ascertainment of the epidemiology of STEC and HUS.

Results: From 1999-2016, 192 patients presented with D+ HUS (0.75-18 years old, median 4): 5 African American, 5 Hispanic, 2 Asian American, and the rest white. 104 were female. 157 (82%) presented in the months Apr to Oct. 54 patients were treated 1999-2005, 90 from 2006-2012 and 47 from 2013-2016. 90 patients had stool cultures + for E coli O157:H7 and 2 for E coli O145. Of those with negative stool culture, 4 had stool Shiga toxin detected by PCR and 52 had serologic evidence for E. coli O157:H7. In the last time frame, 11 stools were identified as STEC by molecular analysis without a stool culture. 96 patients (50%) required acute dialysis; 61 were treated with PD, 23 - HD, 3 - CRRT, and 9 - multiple modalities.

9 patients had intraabdominal processes requiring operative intervention, 5 with intestinal perforation, of whom all survived. 12 patients developed neurologic complications including seizures, cerebral infarctions and cerebral edema. 3 died, 4 survived with severe neurologic impairment and 5 recovered normal cognitive function. The 3 deaths in this cohort of D+HUS patients represent a mortality rate of 1.6%. At discharge, 8 patients required ongoing dialysis or had eGFR < 30 ml/min/1.73 m². Epidemiologic analysis showed STEC incidence rates for 7 TN counties from 2006 - 2015 to be 6.3 -9 cases/ 100,000 population per year, significantly exceeding the overall US rate of 0.6 - 1.8 for 1996-2011.

Conclusions: D+ HUS after STEC continues to be a common cause of pediatric acute kidney injury with significant morbidity and mortality. Given lack of specific therapy, intensified education and geographically-targeted public health measures to limit food and environmental exposure to E.coli O157:H7 may be warranted.

END STAGE RENAL DISEASE AS THE UNFAVORABLE OUTCOME OF PNEUMOCOCCAL-ASSOCIATED HEMOLYTIC UREMIC SYNDROME IN A 2-YEAR OLD BOY

Bjanid O¹, Adamczyk P², Jedzura A¹, Dyga K¹, Trembecka-Dubel E¹, Prohászka Z³, Szczepanska M²

¹*Pediatric Nephrology Ward, University Hospital in Zabrze, Poland;* ²*Department of Pediatrics in Zabrze, Med. Univ. of Silesia, Katowice, Poland;* ³*Semmelweis University, Research Laboratory, Budapest, Hungary*

Background: Hemolytic uremic syndrome (HUS), defined as the triad of symptoms consisting of microangiopathic hemolytic anemia, thrombocytopenia and acute kidney injury has a wide range of causes. About 5% of HUS cases are associated with *Streptococcus pneumoniae* invasive infections (P-HUS). In those cases the prognosis may be poor with mortality rate at 10-15% mainly due to the course of primary disease (meningitis or sepsis). In survivors, the long-term renal outcome is usually considered to be relatively good.

Aim of the study: Authors describe the history of 2-year old boy, who was referred to pediatric surgery ward due to left pleural empyema. After two days of antibiotic treatment progression in the amount of pleural exudation and deterioration in the patient's general condition were observed, requiring videothoracoscopy and pleural cavity drainage. During the perioperative period he became anuric and the laboratory tests revealed features of HUS: severe hemolytic anemia (Hb level 5.9 g/dl), thrombocytopenia (23 G/l), uremia (creatinine level 166 µmol/l, urea level 22,8 mmol/l). Disturbances in complement regulation and ADAMTS-13 activity were excluded. Renal replacement therapy (RRT) was necessary - intermittent, daily HDF sessions were applied together with continuation of combined antibiotic therapy and respiratory therapy. The successful improvement in general condition and regression of disturbances in respiratory system were relatively quickly achieved, however the boy remained anuric for two weeks. During the third week of therapy an increasing urine output was observed. Unfortunately, it was not accompanied by effective improvement in renal clearance - the eGFR became stabilized at around 10 ml/min with constant hyperkalemia and metabolic acidosis. After 6 weeks the RRT modality was changed into automatic peritoneal dialysis and after 3 months the boy was still dialysis-dependant achieving formally the ESRD status.

Conclusions: Regardless the impressive progress in treatment of HUS made in recent years, the renal outcome in P-HUS is still dependant mainly on the natural course of the disease. There is a great need for effective interventions modifying the mechanisms of kidney injury in P-HUS. Perhaps searching for co-existing disturbances in complement regulation may be crucial in some cases as the complication is observed in limited number of patients with *S. pneumoniae* infections.

ECULIZUMAB TREATMENT IN A CHILD WITH STREPTOCOCCUS PNEUMONIAE ASSOCIATED HUS WITH EVIDENCE OF NEURAMINIDASE ACTIVITY AND DECREASED MCP EXPRESSION

Simankova N¹, Vondrak K¹, Pavlicek P², Backai T², Seeman T¹

¹Department of Paediatrics ²Faculty of Medicine Charles University in Prague and University Hospital Motol, ²Department of Anaesthesiology and ICM ²Faculty of Medicine Charles University in Prague and University Hospital Motol

Background: Streptococcus pneumoniae associated HUS (SpHUS) is accompanied with invasive pneumococcal diseases. The diagnosis is based on occurrence of acute hemolytic anemia, thrombocytopenia, acute kidney injury and invasive pneumococcal infections. In recent years there has been an increase in the incidence of invasive Str.pneumoniae infections associated with vaccination. SpHUS is associated with serotypes uncovered by the vaccine Prevnar 7 and 13. We present a case of the girl with necrotising pneumococcal pneumonia, sepsis and HUS symptoms development with evidence of neuraminidase activity, decreased MCP expression and significant complement activation.

Aim of the study: We present a case of the girl with necrotising pneumococcal pneumonia, sepsis and HUS symptoms development with evidence of neuraminidase activity, decreased MCP expression and significant complement activation.

Patients: 5-year-old girl was admitted with quick development of sepsis and MODS. X-ray showed a severe bilateral pneumonia, there were positive a pneumococcal antigen in urine and Str.pneumoniae in the blood culture. Development of septic shock, circulatory failure, acute renal failure, anuria, ARDS, DIC, hepatopathy. Mechanical ventilation and CVVHD were started.

Methods: Laboratory tests and diagnostic procedures: CRP 200 mg/l, creatinine 172 umol/l, LD 50.4 ukat/l, haptoglobin 0,3 g/l, hemoglobin 79 g/l, leucocytes 0.9, blasts 0.016, schistocytes 26%. Coombs with mild positivity. Bone marrow biopsy with no signs of malignancy. Complement activation (C3 0,10 gr/l, C4 <0,02 gr/l). Laboratory evidence of decreased MCP expression and neuraminidase activity. ADAMTS 13: negative, anti-FH antibodies: negative. Treatment: plasmapheresis, bronchoscopy, ATB therapy. Eculizumab administration: 600 mg (day 4), 300 mg (day 11,25 and every other 2 weeks).

Results: Clinical status and pulmonary findings improved, diuresis increased. CVVHD was stopped (day 19). Extubation and weaning (day 21). Renal parameters in normal range (creatinine 20 umol/l), no proteinuria or hematuria, negative HUS activity (PLT 237, schistocytes 0, LDH 6,57). Favorable neurological status. Eculizumab is continued to exclusion of mutation in complement-regulating genes.

Conclusions: The diagnosis of SpHUS can be difficult for concurrent development of DIC and sepsis. In case of complement activation is necessary to think about the overlap with complement-associated atypical HUS. Mortality rate is reported up to 12 %, ESRD 10-16 %, CKD gr. I-IV about 16 %. Administration of eculizumab in early stages can improve overall prognosis.

A7

MAT ASSOCIATED WITH EPISODE OF ULCERATIVE COLITIS

Jarque A¹, Gonzalez-Posada JM¹, Macia M¹, Valga F², Monzón T², Gamba ML³

¹*Nephrology Services and* ³*General Surgery of HUNSC;* ²*Nephrology Services of Clinic Quiron, Santa Cruz de Tenerife Spain*

Aim of the case: Description of a case of MAT in relation to episode of ulcerative colitis.

Patients: 33-year-old male patient with personal history of ulcerative colitis since age 13 - and chronic treatment with Claversal. Father and brother: ankylosing spondylitis.

Admission 2/14/15 for outbreak of ulcerative colitis associated with MAT. UMI admission and initiation of renal replacement therapy. Laboratory data: Hb 6.9 mg / dl, platelets 35000, LDH 2725, Coombs negative direct, haptoglobin <8 mg / dl, INR 1.1, APTT 27 " Activity ADAMTS -13 26%, Creatinine 5.9 mg / dl, urea 146 mg / dl. Negative autoimmune study. Shiga toxin is negative.

Evolution: In the laboratory data and clinical evolution is diagnosed of MAT associated with its underlying disease. After initiation of Hemodialysis and seven sessions of plasmapheresis rescue therapy is decided with Eculizumab. Clinical evolution was favorable, with recovery of renal function at 45 days, with no subsequent need for hemodialysis and recovery of the digestive tract. At discharge, he was maintained on stereo therapy and maintenance therapy with Eculizumab. In the subsequent evolution by Digestive presented a new outbreak of colitis with findings of high-grade dysplasia in serial colonoscopies, which is why a total proctocolectomy is proposed after a year and a half of the MAT episode. The dose was discontinued after septic shock surgery following intervention secondary to perforation of the anastomosis. After clinical stabilization, eculizumab is reintroduced. Currently stable with creatinine of 2.1 mg / dl. The genetic study did not show mutations associated with hemolytic uremic syndrome.

Conclusions: The present case is an unusual clinical situation that reveals the complexity of the activation of the complement system triggered in multiple clinical contexts such as an episode of ulcerative colitis. The use of Eculizumab early in the present case contributed to the stabilization as well as the improvement of renal function. Currently pending evaluation of withdrawal of Eculizumab. The use of Eculizumab as rescue therapy has been previously described in isolated cases of Colitis ulcerosa with good response. In our patient, no associated mutations of the complement system have been found. It remains to be elucidated how long this therapy should be maintained.

B1

PHENOTYPIC STUDIES OF A NOVEL FACTOR B MUTATION IN FAMILIAL ATYPICAL HEMOLYTIC UREMIC SYNDROME

Aradottir S¹, Kristofferson AC¹, Gong H¹, Roumenina LT^{2,3,4}, Palsson R^{5,6}, Karpman D¹

¹*Department of Pediatrics, Clinical Sciences Lund, Lund University, Lund, Sweden;*
²*Université Pierre et Marie Curie, Paris, France ;* ³*INSERM UMRS 1138, Cordeliers Research Center, Paris, France;* ⁴*Université Paris Descartes Sorbonne Paris-Cité, Paris, France ;* ⁵*Landspítali - The National University Hospital of Iceland, Reykjavik, Iceland;* ⁶*University of Iceland, Hringbraut, Reykjavík, Iceland*

Background: Factor B mutations have been reported in atypical hemolytic uremic syndrome aHUS, some of which lead to a hyperfunctional C3 convertase.

Aim of the study: This study describes a novel factor B mutation and its phenotypic consequences.

Patients: A heterozygous factor B mutation (D371G, c.1112A>G) was identified in an Icelandic family in which three male family members developed aHUS. In addition, two unaffected male family members had the mutation. The mutation is located in proximity of the C3b-binding site. Carriers of the mutated factor B gene also have a known factor B polymorphism (R32Q). No other mutations in complement genes were found. All individuals with the mutation (three generations) had normal levels of factor B but low levels of C3.

Results: The factor B size was normal, detected by immunoblotting. Sera containing the mutation led to increased C3 deposition on human glomerular endothelial cells and hemolysis of sheep erythrocytes. The factor B mutation and polymorphism were expressed and secreted and the size corresponded to wild-type factor B. The mutant variant of factor B exhibited increased binding to C3b and thus enhanced formation of the C3 convertase, assayed by surface plasmon resonance. Incubation of the mutant factor B (in factor B-depleted serum) with rabbit erythrocytes resulted in increased hemolysis.

Conclusions: In conclusion, all affected family members demonstrated complement consumption with low C3 levels and their serum led to complement deposition and hemolysis. The mutant factor B demonstrated enhanced C3 convertase formation and hemolysis, providing a potential explanation for the complement consumption and contribution to the development of aHUS.

COMPLEMENT REGULATORY GENE MUTATIONS AND ATYPICAL HEMOLYTIC UREMIC SYNDROME ACQUIRED WITH HEMATOPOIETIC STEM CELL TRANSPLANT

Ardissino G¹, Salardi S², Sgarbanti M², Berra S³, Colussi G⁴, Cugno M⁵, Zecca M⁶, Mina T⁶, Giglio F⁷, Peccatori J⁷, Terruzzi E⁸, Diral E⁸, Tel F¹, Clivio A³, Tedeschi S²

¹Center for HUS Control, Prevention and Management and ²Lab. of Med. Genetics, Fondazione IRCCS Ca' Granda, Milano, Italy; ³Dipartimento di Scienze Biomediche e Cliniche "Luigi Sacco", Università di Milano, Italy; ⁴S.C. Nefrologia, Milano, Italy; ⁵Medicina Interna, Dipartimento di Fisiopatologia Medico Chirurgica, Università degli Studi di Milano, Fondazione IRCCS Ca' Granda, Milano, Italy; ⁶Pediatric Hematology/Oncology, Fondazione IRCCS Policlinico San Matteo, Pavia, Italy; ⁷Hematology and Bone Marrow Transplantation Unit, IRCCS San Raffaele Scientific Institute, Milano, Italy; ⁸Divisione di Ematologia e CTA, Monza, Italy

Background: Hematopoietic stem cell transplant-related thrombotic microangiopathy (HSCTTMA) is a severe complication whose pathophysiology is unknown. In the literature, cases of mutations in recipient complement genes are described, but none in donor's DNA. To the best of our knowledge, the possibility that a mutation responsible for atypical hemolytic uremic syndrome (aHUS) may be "transplanted" with HSCT and become expressed in the recipient has never been hypothesized.

Aim of the study: The aim of the study was to assess whether complement regulatory gene abnormalities responsible for HSCT-TMA can be received from the donor in those cases where the recipient was negative at screening for complement abnormalities.

Patients: Sixteen patients with HSCT-TMA were screened for point mutations and macrorearrangements in genes involved in complement dysregulation. DNA was extracted both from peripheral blood samples (donor DNA) and buccal brushing (recipient DNA).

Methods: Genetic characterization was performed using Next Generation Sequencing on a Miseq (Illumina) platform and Multiplex Ligation-dependent Probe Amplification analysis (SALSA MLPA P236 ARMD -MRC Holland).

Results: In 10 out of 16 patients, screening for known causes of TMA didn't identified mutations neither in recipient nor in donor DNA. In 6 cases, donor complement genetic alterations spread over CFH, CFI, CFB, C3, MCP and CFHR5 genes were found, that were not present in the patient's DNA. In 1 case a CFHR5 variant was revealed in the recipient too.

Conclusions: All detected variants have already been described in patients with complement regulatory protein (CRP) disorders, some with a significant association with aHUS, AMD, or C3G, some others considered predisposing genetic factors for aHUS or affecting the disease penetrance and severity. A possible working hypothesis is that, in our patients, a donor-derived cell population of the monocyte lineage bearing variant in the CRP resulted in the production of a mutated protein responsible for the impairment of the native complement system regulation.

Proofs of liver colonization by donor-derived stem cells and consequent inheritance of pathological risk factors have been demonstrated in some other settings.

The donor may not have experienced the disease given its low penetrance and because of the absence of adequate triggers activating complement; whereas such triggers are all present in recipients undergoing HSCT.

B3

DETECTION OF CONVERTASE-STABILIZING FACTORS IN PATIENTS WITH COMPLEMENT-MEDIATED RENAL DISEASES

Michels MA¹, Okroj M², Blom AM³, van Kraaij SA¹, van de Kar NC¹, Volokhina EB^{1,4*}, van den Heuvel LP^{1,4,5*}

¹Dept. of Pediatric Nephrology, Radboudumc, Nijmegen, the Netherlands; ²Dept. of Medical Biotechnology, Intercollegiate Faculty of Biotechnology UG-MUG, Medical University of Gdańsk, Poland; ³Medical Protein Chemistry, Dept. of Translational Medicine, Lund University, Malmö, Sweden; ⁴Dep. of Laboratory Medicine, Radboudumc, Nijmegen, the Netherlands; ⁵Dep. of Pediatrics, University Hospitals Leuven, Leuven, Belgium. *Contributed equally

Background: The autoantibody C3 nephritic factor (C3NeF) plays a pathogenic role in C3 glomerulopathy (C3G) by stabilizing the key enzyme of complement, the C3 convertase. However, reliability of currently used assays to detect C3NeF is limited.

Aim of the study: Recently, we developed a method to measure convertase stability in whole human serum. We now optimized the method for simple detection of convertase-stabilizing factors such as C3NeF in large patient cohorts.

Methods/Patients: Convertase stability was measured in a hemolytic assay using the C5-blocker eculizumab to separate the alternative pathway (AP) into two steps: formation of C3/C5 convertases in a time-variable step 1 and formation of lytic membrane attack complexes in a standardized step 2 for readout. Samples of 15 controls, 33 patients with C3G or related disorders, and family members with Factor B (FB) mutation (p.Lys323Glu) and atypical hemolytic uremic syndrome (aHUS) were analyzed.

Results: In all healthy controls convertase activity dropped to background levels from t=30 min. When serum or purified Ig-fraction containing C3NeF was added to control serum, convertase activity was increased at t=30. In our cohort 17 out of 33 (52%) patients showed increased convertase stability, *i.e.* detectable convertase activity at t=30 or later. Interestingly, prolonged activity was also detected in an aHUS family and segregated with the FB mutation in affected and non-affected family members.

Conclusion: We present optimization of a simple and reliable assay to detect convertase-stabilizing factors (C3NeF and mutations) in complement-mediated disease.

GENETIC TESTING OF CFHR1 AND CFHR3 GENE DELETIONS IN A GROUP OF PEDIATRIC PATIENTS WITH ATYPIC HEMOLYTIC UREMIC SYNDROME

Stolbova S¹, Zieg J¹, Simankova N¹, Pruhova S¹, Bezdicka M², Cinek O², Seeman T¹

¹Department of Pediatrics, Second Faculty of Medicine, Charles University in Prague and University Hospital Motol, Prague, Czech Republic; ²Laboratory of molecular genetics, Second Faculty of Medicine, Charles University in Prague and University Hospital Motol, Prague, Czech Republic

Background: In a group of patients with atypical hemolytic uremic syndrome (aHUS) have also been found to have autoantibodies against Factor H (10-15% of cases). More than 90% cases are associated with homozygous deletions within the complement factor H-related genes - *CFHR1* and *CFHR3*.

Aim of the study: The aim of the study was to perform genetic testing of all our patients with aHUS to identify a number of patients with deletions of *CFHR1* and *CFHR3* genes.

Patients: We tested a group of 21 Czech pediatric patients with aHUS. 14 patients (66%) have autoantibodies against Factor H, one patient has also mutation of *CFH* gene. 7 patients (44%) did not have autoantibodies against Factor H, in two patient was found mutation of *MCP* gene and in one patient mutation of *CFH* gene.

Methods: We performed Multiplex ligation-dependent probe amplification (MLPA) in a group of 21 patients with atypical hemolytic uremic syndrome.

Results: In 12 patients we found homozygous deletions of *CFHR1* and *CFHR3* gene. One patient has homozygous deletion in *CFHR1* gene and heterozygous deletion in *CFHR3* gene. In one patient we found heterozygous deletions in both *CFHR1* and *CFHR3* genes. One patient has fusion of *CFH* and *CFHR1* genes and deletion of *CFHR3* gene.

Conclusions: In conclusion, 93% of patients with Anti-Factor H autoantibody-associated hemolytic uremic syndrome have homozygous deletion of *CFHR1* gene. In 85% of patients we found homozygous deletions in both *CFHR1* and *CFHR3* gene.

ESTABLISHMENT OF A COMPREHENSIVE COMPLEMENT EXAMINATION SYSTEM FOR COMPLEMENT-RELATED DISEASES BY THE JAPANESE ASSOCIATION FOR COMPLEMENT RESEARCH

Hidaka Y^{1,3}, Inoue N^{2,3}, Ohtsuka Y³, Sawai T³, Miyata T³, Osawa I², Ohtani K², Okada H², Kinoshita T², Sekine H², Tsukamoto H², Nakao M², Mizuno M², Murakami Y², Horiuchi T², Wakamiya N²

¹*Department of Pediatrics, Shinshu University School of Medicine, Matsumoto, Nagano, Japan;* ²*Board, The Japanese Association for Complement Research, Osaka, Japan;* ³*TMA registry team, The Japanese Association for Complement Research, Osaka, Japan*

Background: In recent years, it has become clear that atypical hemolytic uremic syndrome (aHUS) and C3 glomerulopathy are caused by abnormal complement activation due to complement-related gene mutations. Therefore the necessity and importance of comprehensive complement examinations for the diagnoses of complement-related diseases has increased. Since 2015, the Japanese Association for Complement Research (JACR) has been preparing a complement examination system aiming at the elucidation of pathological mechanisms and the development of a new diagnostic procedure for complement-related diseases. We have started a registry system for thrombotic microangiopathy (TMA).

Aim of the study: Establishment of a comprehensive complement examination system for complement-related diseases by JACR.

Methods: The attempt is comprised of the construction of an examination system for complement-related proteins, a mutation analysis system for complement-related genes, a registry system for complement-related diseases, and a support system for medical personnel. To examine complement-related proteins, we have been examined 8 items of C3, C4, CH50, sC5b-9, Ba, CFH, CFH-Ig, and C5a. For the genetic analysis, we have been using a next-generation sequencer for 115 genes and have confirmed mutations by Sanger method for seven genes, regarded as important in aHUS. In the registry system, we have used REDCap (Research Electronic Data Capture) developed at Vanderbilt University. For the support system, we have formed a professional team comprised of JACR member, which supports medical personnel with our examination results.

Results: In the TMA registry, now 16 patients (aHUS suspected were 11, secondary TMA were 5) were examined for complement-related proteins and genes. Although there is no evident pathogenic mutation in them, we have found that two each have CFH rare variant which is able to drive the complement activation. We observed the increasing of sC5b-9, and Ba but not so high rate in that of C5a in TMA patients.

Conclusions: We will present our current progress in this conference.

EARLY FETAL OUTCOME OF 28 PREGNANCIES IN WOMEN WITH ATYPICAL HEMOLYTIC UREMIC SYNDROME

Gaggi M¹, Aigner C¹, Haninger N¹, Prohászka Z², Kain R³, Sunder-Plassmann R⁴, Sunder-Plassmann G¹, Alice Schmidt A¹

¹*Div. of Nephrol. & Dialysis, Dept. of Medicine III, Med. Univ. Vienna, Vienna, Austria;* ²*Res. Lab., IIIrd Dept. of Internal Medicine, Semmelweis University, Budapest, Hungary;* ³*Clin. Inst. of Pathol., Med. Univ. Vienna, Vienna, Austria;* ⁴*Genetics Lab., Dept. of Lab. Medicine, Med. Univ. Vienna, Vienna, Austria*

Background: Pregnancy is a high-risk scenario for women with a history of aHUS and about 20% of female cases first present in relation to pregnancy. Classically, pregnancy-aHUS presents in the postpartum period and is thought to have little effect on fetal outcome. However, there is accumulating evidence that aHUS in mothers can lead to worse fetal outcome. Indeed, HELLP syndrome (hemolysis - elevated liver enzymes - low platelet syndrome) and (pre-)eclampsia, which are both strongly linked to complement dysregulation, may present undetected aHUS episodes with potential worse fetal outcomes

Aim of the study: The study aimed to analyze early fetal outcome of pregnancies in women with a history of aHUS.

Patients: Up until 2016 we recorded 28 pregnancies in 14 women with clinically diagnosed aHUS (clinical course, laboratory and genetic analysis, renal biopsy).

Methods: We retrospectively analyzed early fetal outcome of 28 pregnancies by means of chart review, personal interview of the mother, and the Austrian mother/child-book (Mutter-Kind-Pass) if available.

Results: The median gestational age at birth was 38 weeks (interquartile range: 33.5, 40), 9 were female, 12 were male, and in 5 the sex was undeterminable (2 cases missing). Of the 28 pregnancies 20 (71%) resulted in a term live birth, 2 (7%) were preterm live births, and 2 (7%) were preterm stillbirths. Four (14%) pregnancies led to an abortion prior to gestational week 21, of which one was induced due to fetal death. Of note, for 15 (54%) pregnancies the mode of delivery was c-section, of which 4 (27%) were emergency surgeries. Seven (25%) pregnancies led to pregnancy-associated aHUS, of which 4 women presented post partum (2 term live birth, 1 preterm live birth, 1 spontaneous abortion at gestational week 18). Three women presented antepartum as HELLP/preeclampsia, which led to 1 preterm stillbirth and 3 abortions prior to week 21 (one induced due to fetal death). All live births were appropriate for gestational age, except for one newborn, who was large for gestational age. The mean birth weight (in cases with delivery later than gestational week 21 (2 cases missing)) was 3145±862 grams, the mean height was 50.1±3.2 centimeters, and the mean head circumference was 34.8±1.6 centimeters. Taken together, the prevalence of adverse fetal outcome in our cohort was 21 (95%CI: 10, 40) per 100 pregnancies in women with aHUS and 70 (95%CI: 33, 93) per 100 p-aHUS episodes.

Conclusions: Early outcome of newborns from mothers with a history of aHUS without or a post partum aHUS episode is comparable with those from healthy mothers. However, in case of complement dysregulation during pregnancy fetal outcome is significantly worse compared to the former scenarios. It remains unclear if early miscarriages and abortions are directly related to aHUS, but overall adverse fetal outcome is underestimated in women with a history of aHUS.

C1

INTERFERON-BETA (IFN- β) THERAPY MAY INDUCE SUSTAINED ATYPICAL HEMOLYTIC-UREMIC SYNDROME (aHUS) RESISTANT TO PLASMA EXCHANGE (PE) AND RESPONSIVE TO ECULIZUMAB TREATMENT. A CASE REPORT

Colucci V, Di Leo V, Cianciotta F, Villani C, Giliberti M, Gallo P, Verdesca SVS, Manno C, Rossini M, Gesualdo L, Montinaro V

Division of Nephrology, Azienda Ospedaliero-Universitaria Policlinico and University of Bari, Italy

Background: IFN- β is an immunomodulating agent for relapsing forms of multiple sclerosis (MS). Renal adverse effects of IFN- β therapy include infrequent cases of aHUS. Interruption of IFN therapy determines an amelioration of microangiopathic symptoms and renal function recovery.

Aim of the study: The aim of the study was to assess whether treatment with Eculizumab in a sustained aHUS induced by IFN- β could reverse the microangiopathic process.

Patients: We report a clinical case of a 42 years-old Caucasian patient suffering from MS, treated by IFN- β that developed an aHUS resistant to plasma exchange and responsive to Eculizumab.

Results: MS was diagnosed in 1996. Treatment with IFN- β was well tolerated for a long period. In February 2016, pat. was admitted for tonsillitis and IFN- β was stopped; concomitantly he presented hemolytic anemia, thrombocytopenia, elevated LDH, reduced haptoglobin and renal insufficiency with severe hypertension. Microbiological tests were negative, ADAMTS 13 activity was normal, and C3 and C4 reduced. Clinical diagnosis of aHUS prompted a treatment with PE; hemodialysis was also needed. Given the poor response to PE, therapy with Eculizumab was started that produced a quick clinical improvement. Renal biopsy was performed, that showed both acute and chronic lesions of thrombotic microangiopathy. After the ninth infusion, Eculizumab was stopped due to the appearance of acute hepatitis C. However, at the same time renal function had improved and, after four months, hemodialysis was stopped. After 1 year from the onset, renal function keeps improving (eGFR 63 ml/min/1.73 m²), there are no signs of microangiopathy and the HCV virus was cleared after a 12 weeks treatment with DAA.

Conclusions: IFN- β treatment can induce aHUS that may not be promptly reversible after withdrawal of the drug. In this clinical case, Eculizumab treatment was efficacious in halting the secondary microangiopathic phenomenon, allowing a favorable outcome of renal failure.

ECULIZUMAB RESULTED IN COMPLETE RENAL RECOVERY AFTER 9 MONTHS OF DIALYSIS IN CHILD WITH ATYPICAL HEMOLYTIC UREMIC SYNDROME

Alzabli SM¹, Rahim KA¹, Anazi AA¹

¹Pediatric Nephrology Section- Children Specialized Hospital, King Fahad Medical City, Riyadh, Saudi Arabia

Background: Atypical haemolytic uraemic syndrome (aHUS) is rare, life-threatening, genetic disease characterized by microangiopathic hemolytic anemia, thrombocytopenia, and renal injury. Plasma therapy was the mainstay of treatment, with over 50 % of patients either died or developed permanent kidney damage within the first year. Eculizumab is a monoclonal antibody that blocks the cleavage of C5. Prospective trials demonstrated its effectiveness in management of aHUS.

Patients: We report a 3 year old boy, with partial aHUS presented with renal impairment, anemia, normal platelets, low C3, low Complement Factor I and B (CFI & CFB). First kidney biopsy showed proliferative glomerulonephritis, vascular changes without obvious thrombosis. Genetic analysis came positive for mutations in CFI and C3 genes. Second biopsy while on dialysis was consistent with aHUS.

Methods: Steroid pulse therapy and plasmapheresis were ineffective to control the disease, peritoneal dialysis then started. Despite vigorous antihypertensive treatment and improved fluid overload with dialysis, HTN persisted. Eculizumab was given (after 3 months of dialysis).

Results: Eculizumab resulted in renal recovery and cessation of prolonged dialysis. Renal function improved after the second dose. PD catheter was removed after 9 months of dialysis. Currently, after 16 months of Eculizumab therapy, disease is in remission and renal function is normal.

Conclusions: Eculizumab leads to complete renal recovery after 9 months of dialysis dependency. Partial HUS to be considered; diagnosis to be confirmed by biopsy and or gene mutations.

COMPLEMENT FACTOR H MUTATION ATYPICAL HEMOLYTIC UREMIC SYNDROME - 10 MONTH ON DIALYSIS WITH PARTIAL RECOVERY OF THE RENAL FUNCTION AFTER ECULIZUMAB THERAPY - CASE REPORT

Lungu A¹, Tacu D², Captanescu A², Stoica C¹, Prohaszka Z⁴

¹Fundeni Clin. Inst., Ped. Nephrol., Bucharest, Romania; ²Fundeni Clin. Inst., Renal Transplant. Unit, Bucharest, Romania; ³Carol Davila Nephrol. Hosp., Nephrol. Dept., Bucharest, Romania; ⁴Semmelweis Univ., Res. Lab., Budapest, Hungary

Introduction: Distinct genetic changes in Complement Factor H (CFH), a key regulator of the alternative pathway, are associated with atypical Hemolytic Uremic Syndrome (aHUS).

Case summary: A 19 years old boy was admitted to our Hospital in July 2015 feeling sick for a couple of days, pale, hypertensive and with low urine output. Initial blood work showed decreased Haemoglobin, decreased Platelets, increased Lactic dehydrogenase (LDH), increased Urea and Creatinine, decreased Haptoglobin, decreased C3 and normal C4.

Initial diagnosis of Hemolytic Uremic Syndrome was made. He had no history of diarrhea, stool E. Coli and Shiga toxin were negative.

Treatment was started with Plasma Exchange (PEX) and Hemodialysis (HD). After a good initial response to PEX, he suffered a relapse.

Blood and serum were sent for extensive complement and genetic testing to Semmelweis University, Budapest.

The patient was found to carry several aHUS risk variation: a mutation in CFH (p.E1198Q) that is expected to have a pathogenic role in the development of aHUS. (This mutation was not reported previously in aHUS patients or healthy individuals, but two mutations (E1198K and E1198A) affecting the same amino acid as the identified mutation were reported in aHUS patients and both mutants were shown to exhibit functional defects). He also showed two risk haplotypes: a homozygous one in CFH (H3), and a heterozygous one in MCP (MCPggaac). These variations together explain the genetic background of the alternative pathway dysregulation, hence, support the diagnosis of *complement-mediated atypical HUS*.

ECULIZUMAB treatment was started in November 2015, four months after the onset of disease.

After six months of Eculizumab therapy and ten months on hemodialysis, the kidney function recovered partially so we could stop renal replacement therapy in April 2016.

We tested C5b-9 deposits on microvascular endothelial cells (HMEC) (Istituto di Ricerca Farmacologiche MARIO Negri, Italy). The test showed normal C5b-9 deposits under Eculizumab treatment.

His kidney function is continuously improving, and now he is at an eGFR of 42 ml/min/1.73m² (MDRD) with a creatinine of 2.23 mg/dl. He has good clinical status and well-controlled blood pressure.

He re-entered his normal social life, he finished high school and entered an economics college.

Conclusion: In many cases, the atypical Hemolytic Uremic Syndrome is caused by a sum of genetic abnormalities in the complement cascade.

Late start of Eculizumab therapy could stop the progression of renal disease and the patients can partially recover the kidney function.

POSTERIOR REVERSIBLE ENCEPHALOPATHY SYNDROME COMPLICATING ATYPICAL HEMOLYTIC UREMIC SYNDROME: POSITIVE EFFECT OF ECULIZUMAB

Di Leo V, Cianciotta F, Colucci V, D'Ettoire G, Matino S, Cataldo E, Taurisano M, Mercurio U, Manno C, Rossini M, Gesualdo L, Montinaro V

Division of Nephrology, Azienda Ospedaliero-Universitaria Policlinico and University of Bari, Italy

Background: Posterior Reversible Encephalopathy Syndrome (PRES) is induced by vasogenic edema predominantly in the occipital lobes and it is initiated by increased blood pressure, taking immunosuppressive drugs, or renal insufficiency.

Aim of the study: The aim of the study was to describe whether treatment with Eculizumab could reverse clinical symptoms associated to PRES in a patient with Atypical Hemolytic Uremic Syndrome (aHUS) with neurological involvement.

Patients: We describe a case of PRES in a young man with the diagnosis of aHUS.

Results: A 30-year-old Caucasian man was admitted to our Unit because of a 2-months history of arthralgias, malaise, vomiting, edema and headache. The first laboratory tests revealed: hemolytic anemia with schizocytes on peripheral smear, thrombocytopenia, elevated levels of LDH, low levels of haptoglobin and acute renal failure. Shiga toxin-producing *Escherichia coli* was negative, ADAMTS 13 activity was normal, only C3 levels were low, Coombs test was negative. He was severely hypertensive. Renal biopsy showed a thrombotic microangiopathy consistent with a clinical diagnosis of aHUS. Intensive plasma exchange (PEX) sessions with fresh frozen plasma were started; also, hemodialysis (HD) was required due to the worsening of renal function. Microangiopathic signs subsided. During the 4th week of HD and PEX, after a session of PEX, the patient developed hypertensive crisis followed by grand-mal seizures and coma that required admission to the Intensive Care Unit. Brain magnetic resonance imaging (MRI) showed parietal-occipital lobe edema consistent with PRES. At this time there was evidence of recurrence of aHUS. Seizures were initially managed with antiepileptics and tight blood pressure control (sodium nitroprusside). We started therapy with Eculizumab, an anti-C5 antibody. Four hours after the infusion the patient awoke from coma and his neurological conditions improved rapidly. MRI, performed 7 days after seizures, was normal. The patient is currently off antiepileptics with no further seizures and well-controlled blood pressure but he continues hemodialysis.

Conclusions: Eculizumab, offering a pathophysiologic-based treatment, could be useful to treat PRES during the acute phase of aHUS and to avoid neurological irreversible lesions, which are described in some clinical conditions (acute renal failure, eclampsia and HUS).

KIDNEY TRANSPLANT IN ATYPICAL HUS DURING ECULIZUMAB ERA. A SINGLE CENTER EXPERIENCE

Ardissino G¹, Cresseri D², Giussani A³, Tel F¹, Cugno M⁴, Corti F.⁵, Testa S¹, Perrone M¹, Sgarbanti M⁶, Strumbo B⁶, Cardillo M⁷, Nocco A⁷, Furian L⁸, Tedeschi S⁶, Beretta C³

Center for HUS Prevention Control and Management at the: ¹Dept. of Pediatrics, ²Nephrology Unit; ³Kidney Transplant Unit; ⁴Internal Medicine; ⁵Pharmacy; ⁶Medical Genetics, ⁷North Italian Transplant, Fondazione IRCCS Ca' Granda Osp. Maggiore Policlinico, Milano and ⁸Transplantation Unit, University Hospital, Padova, Italy

Background: For decades, atypical hemolytic uremic syndrome (aHUS) has been considered a contraindication to kidney transplant (KTx) for the very high risk of disease recurrence. The availability of Eculizumab (ECU) has made it possible to safely address patients (pts) with aHUS to KTx but the best approach to treatment (Rx) as to timing of 1st dosing, schedule, possibility of Rx discontinuation and pt's monitoring, is not well established.

Aim of the study: to describe the experience on KTx in patients with aHUS at our Center during the last decades.

Patients and methods: during the past 25 years, a total 21 pts (6 children) with aHUS were followed for KTx (in 3 KTx had been performed elsewhere). Five pts had a previous KTx. The median time on RRT prior to KTx was 7.0 years. One pt has received the graft from a living-related donor. CFH-related disease (n:15) was the most common etiology followed by mutations on CFI (n:3), C3 (n:1), MCP (n:1) and Idiopathic (n:1). Based on the strategy used to prevent disease relapse before and after KTx, 3 groups can be identified (some pts were exposed to multiple preventive strategies): A: no prophylaxis (n:9); B: plasmaexchange/plasmapheresis (n:6); C: ECU (n:16).

Results:

	Group	A	B	C
Etiology (CFH-related/other)		6/9	5/1	14/2
Cumulative observation period on KTx (yrs)		55.8	9.6	45.8
Relapse rate (event/patient/10 yrs)		0.7	3.1	0.0

Pts in group B were switched to ECU once available. One pt discontinued ECU as soon as AntiCFHAb were no longer detectable. Based on complement activity out of the 14 pts currently on ECU, 5 are regularly receiving the infusion every 3 weeks and 9 every 4 weeks.

Conclusions: Our experience favours the prophylactic use of ECU in pts undergoing KTx with a history of aHUS. We recommend complete characterization (as to disease etiology) pre-KTx and that maintenance Rx is continued lifelong.

C6

AN ATYPICAL COURSE FOR ATYPICAL HAEMOLYTIC UREMIC SYNDROME-COMBINED LIVER KIDNEY TRANSPLANT OR LONG TERM ECULIZUMAB THERAPY?

Wong W, Kara T, Prestidge C, Erickson RE

Department of Nephrology, Starship Children's Hospital, Auckland, New Zealand

Background: Isolated kidney transplantation in genetic causes of aHUS is associated with a high risk of disease recurrence with either rapid or eventual graft failure. The availability of eculizumab has dramatically improved renal allograft survival but with substantial financial cost. An alternative is combined liver and kidney transplant which replaces the mutant protein and offers a "cure" for the condition. A dual organ transplant presents significant risk to the recipient. We present a 13.5 year male for discussion of the "preferred approach" in the management of his end stage kidney disease.

Patient: A 13.5year male Caucasian progressed to end stage renal failure after 12.5 years of chronic kidney disease following an attack of aHUS episode at age 9months. Renal biopsy confirmed aHUS. He was treated with fresh frozen plasma for 30months which slowly tapered. A C3 heterozygous gene mutation (c.3474 C>G p.C1136w) was detected. He recovered from the episode but continued to have severe hypertension and reduced renal function. He had not further documented episodes of thrombotic micro-angiopathy for the next 12.5 years.

The patient was acutely admitted to hospital with severe hypertension, acute pulmonary oedema and deteriorating renal function at age 13.5 years. Peritoneal dialysis was initiated with significant improvement in fluid balance and blood pressure control. His haematological and biochemical laboratory markers are shown.

Questions:

- 1) Does the patient's atypical clinical course predict his risk for recurrence following renal transplantation?
- 2) Should he have an isolated kidney transplant in view of his clinical course
- 3) Is a combined liver kidney transplant the only means of ensuring "cure" of his aHUS?
- 4) Can the patient's risk of disease recurrence be estimated from his C3 mutation?

THROMBOTIC MICROANGIOPATHY IN THE FRAME OF SYSTEMIC DISEASES: FOUR CASES FROM PEDIATRIC CLINICAL PRACTICE

Rosales A¹, Madrid A¹, Muñoz M¹, Quintero J¹, Alonso L¹, Rodríguez de Córdoba S², Ariceta G¹

¹Hospital Universitario Vall d'Hebron, Barcelona, Spain; ²Consejo Superior de Investigaciones Científicas, Madrid, Spain

Background: Thrombotic microangiopathies result from the interaction between predisposing factors and triggering events. We present four pediatric cases with unusual forms of thrombotic microangiopathy in the frame of systemic diseases.

Patients: Case 1: 5 years old, acute pancreatitis with complement activation and HUS-triad (hemolytic anemia, thrombocytopenia and acute renal failure). Early treatment with Eculizumab results in rapid hematological and renal remission. MRI shows anatomic variant (pancreas divisum) associated to high risk of spontaneous pancreatitis. Recurrence of pancreatitis under treatment with Eculizumab, with no signs of TMA. Genetic analysis shows risk haplotypes in CHF, MCP and CFHR3-CFHR1 deletion. Pancreatitis triggered aHUS or vice versa?

Case 2: 2 years old, acute myeloid leukemia M5, after haploidentical BMT, complete chimerism. After BMT develops transfusion-dependent anemia, malignant hypertension and proteinuria. Transitory stabilization after suspension of cyclosporine. Progressive disease with two-fold increase of creatinine, renal biopsy shows TMA. Under treatment with Eculizumab normalization of blood pressure and renal function, no proteinuria. Hemoglobin recovery, no need for transfusions. Material for genetic testing from saliva (blood cells from donor), result pending.

Case 3: 15 years old, previously healthy, presents with cholestasis and HUS-triad. Ocular evaluation shows Keyser-Fleischer Ring. Copper in urine and low ceruloplasmin confirm diagnosis of Wilson's disease. Hemolytic anemia only better under treatment with Trientine. Progressive recovery of hemoglobin and renal function. Marked complement activation, CFB-Antibodies and CFHR5 variant.

Case 4: 10 years old, Wilson's disease. 3 years after liver transplantation presents HUS-triad in the frame of viral infection. Recovery after suspension of treatment with Tacrolimus and Everolimus. Carrier of CHR1 and 3 homozygous deletions.

Conclusions: These cases picture the relevance of considering TMA in non-aHUS related diseases in which complement activation and endothelial damage may be trigger or consequence of complement activation. The relevance of complement gene polymorphisms as TMA predisposing condition is not yet well understood.

TIMING OF ECULIZUMAB TREATMENT AND RENAL OUTCOME IN ATYPICAL HUS

Tel F, Cresseri D, Testa S, Paglialonga F, Perrone M, Sgarbanti M, Strumbo B, Tedeschi S, Cugno M, Ardissino G

Center for HUS Prevention Control and Management at the: Dept. of Pediatrics, Nephrology Unit, Medical Genetics, Laboratory, Internal Medicine, Pharmacy Fondazione IRCCS Ca' Granda Osp. Maggiore Policlinico, Milano, Italy

Background: atypical HUS (aHUS) for which the anti complement agent Eculizumab (ECU) is the frontline treatment (Rx) but, for several reasons ECU is not always started early after diagnosis and late Rx may result in permanent renal damage.

Aim of the study: herein, we analyze the renal outcome of patients (Pts) treated at our Center for aHUS with regard to timing of ECU Rx.

Patients: since 2009, at least 49 acute episodes of aHUS in 41 Pts with ongoing TMA, were treated with ECU. The 17 Pts with bone marrow transplantation-related TMA, were excluded for the different pathogenesis and the systematically different (poor) response to ECU Rx. Twelve Pts were children, 25 females, 4 were kidney transplant recipients, median age was 29.3 years (IR 11.7-44.2), 25 episodes had been treated with plasmaexchange (PEX) before ECU and 27 required RRT.

Methods: in 26 events, ECU was started within 15 days of presentation (median 2.5; IR 1-6) while in the remaining 23, Rx was started at a median of 43 days (IR 30-165). Five events (19%) treated early, had also been exposed to PEX before ECU compared to 20 (87%) in the late Rx group.

Results: Pts who started ECU earlier (<15 days) compared with those who started after 15 days since diagnosis had a significantly better outcome as to overall response rate (100 vs 70%), need for acute RRT (23 vs 91%), nadir of sCr (0.74 vs 1.90 md/dL) and median time to reach the nadir od sCr (37 vs 272)

Conclusions: The better outcome with early treatment turns into significantly lower costs for several reasons including the possibility of early discontinuation of ECU, for which a good residual renal function is an essential condition. However, we stress that ECU Rx has been useful even in cases where Rx has been started late, therefore, as long as signs of ongoing TMA are present, we encourage to treat Pts regardless of disease duration.

SUPPORTED BY



Pharma



Dia-Chrom Handelsges.m.b.H.



SUPPORTED BY

The Alexion logo features the word "ALEXION" in a bold, blue, sans-serif font. A thick blue arc starts above the letter 'A' and curves over the 'X' and 'I'. A small red trident-like symbol is positioned above the 'I'.



octapharma[®]

For the safe and optimal use of human proteins